HEPATIC STEATOSIS AND THE DIABETES EPIDEMIC; BIRDS OF A FEATHER

Harold T. Pretorius, M.D.,Ph.D,^ Dennis E. Menke, A.A.,^ Nichole M. Richards, B.S., C.N.M.T.,^Elizabeth Alexander, R.N.,^ Betsy Budke C.N.M.T.

Objective: Describe quantitative liver SPECT analysis to assess hepatic steatosis and aid with its follow-up and treatment.

Methods: SPECT liver-spleen scans were used for liver disease related to hepatotoxins or endocrinopathy including insulin resistance (IR), Cushing's syndrome (CS), diabetes mellitus (DM), thyroid disease (TD) or obesity. Modified fractal analysis used A= (average/peak) counts within hepatic isocontours, I. Regression analysis of Ln(I) vs. Ln(A) yiends a near (0,0) intercept-limiting slope, M and normalized Mn = M(L)(S)/70 for vertical liver (L) and spleen (S) span in cm. Liver disease was confirmed by CT, ultrasound or biopsy; cognitive function by Montreal Cognitive Assessment, IR by HbA1c, CS by high serum cortisol and obesity by BMI.

Results or Case Presentation: Among 65 patients, 37 female, 28 male, age 50+-14 years, were untreated: 9/46 (20%) near normal with Mn 0.96+-0.10; 14/46 (30%) hepatic steatosis with Mn 1.51+-0.15; 13/46 (28%) hepatic fibrosis with Mn 2.05+-0.17 and 10/46 (22%) cirrhosis with Mn 2.78+-0.27. Only 6/53 (11%) with Mn > 1.16 had high liver enzymes. Comorbidities included: obesity 55/65 (85%); hypertension, portal 20/65 (31%), pulmonary 4/65 (6.2%) or systemic 35/65 (54%); IR 20/65 (31%); DM 26/65 (40%); TD 19/65 (29%); CS 4/65 (6.2%); coronary disease 10/65 (16%); heart failure 7/65 (11%); hyperlipidemia 32/65 (49%); TIA or stroke 8/65 (12%), renal disease 5/65 (7.7%); depression, unipolar 19/65 (29%), or bipolar 4/65 (6.1%); chronic anxiety 4/65 (6.2%) or PTSD 2/65 (3.1%), opiate-dependent chronic pain 12/65 (18%); cognitive impairment 18/39 (46.1%); and substance abuse, alcohol 8/65 (12%) or nonalcoholic 4/65 (6.2%). Treatment with > 3600 mg omega 3 fish oil, 400 units vitamin E and/or phentermine/topiramate 7.5/46 mg oral daily for > 6 months tended to reduce Mn with stability or improvement in all comorbidities, even in a cirrhotic patient whose Mn decreased from 4.4 to 2.9.

Discussion: Liver SPECT is more sensitive than liver enzymes, noninvasive, and less expensive than combined CT for hepatic steatosis and MRI for hepatic fibrosis. Although liver SPECT may be nonspecific, epidemic hepatic steatosis will nonetheless account for the preponderance of abnormalities. Liver disease is intrinsic to obesity-related IR, its progression to DM and its comorbidities. Medical therapy for weight loss or mifepristone for mild, often unrecognized CS, may be cost effective vs. invasive, bariatric surgery.

Conclusion: Liver SPECT heterogeneity is readily quantified to sensitively assess liver function; moreover, its use to monitor effective therapy of early liver disease may help to control the epidemic of obesity-related medical and neuropsychiatric comorbidities.

1. Fig. 1. Distribution of normalized, modified fractal slopes: Near normal Mn 0.83+-0.13 for 27/212 (12.7%); hepatic steatosis Mn 1.48+-0.28 for 89/212 (42.0%); hepatic fibrosis Mn 2.30+-0.19 for 38/212 (17.9%); hepatic cirrhosis Mn 3.09+-0.32 for 51/212 (24.1%), not counting outliers with Mn > 4. One patient with acute, obstructive jaundice fell in the cirrhosis category. See Fig. 2 for further description of how Mn is determined.

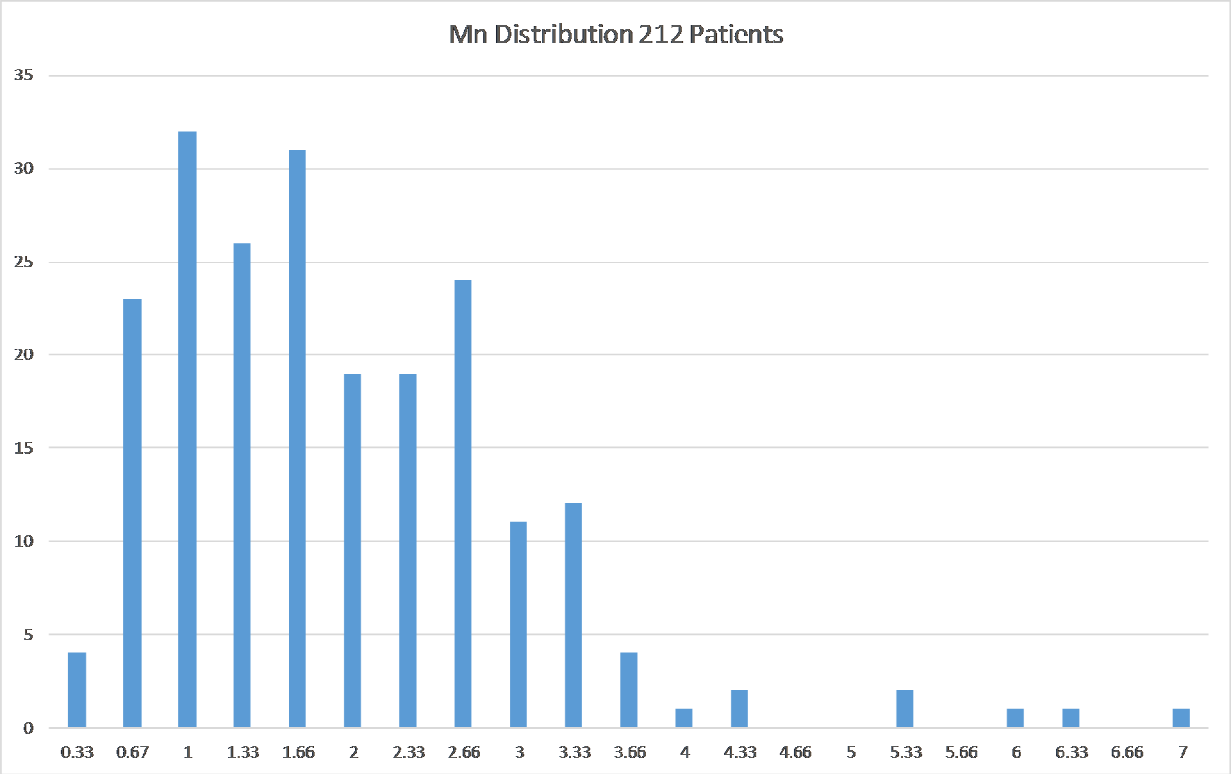

^ From Blue Ash Nuclear Medicine LLC, 4743 Cornell Rd, Cincinnati, OH, 45241 USA and *The Christ Hospital, Cincinnati, OH, 45219, USA.

2. Fig. 2A. Modified fractal slope M determination: Isocontours containing activity greater than specific percentages of peak hepatic activity were drawn by computer software (esoft, Siemens) which also determined average activity within each isocontour. Natural log plots of LN (I) vs LN[(Average Counts)/(Peak counts)] extrapolate to (0,0) since both parameters approach 1 whose LN = 0. Limiting slopes were determined by minimum intercepts and Excel 2013 correlation coefficients nearest to 1, as shown in the example below.

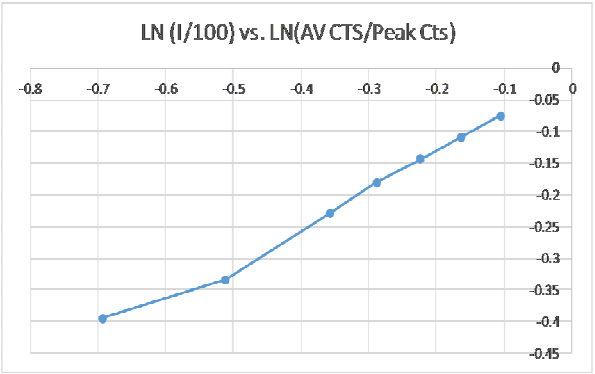

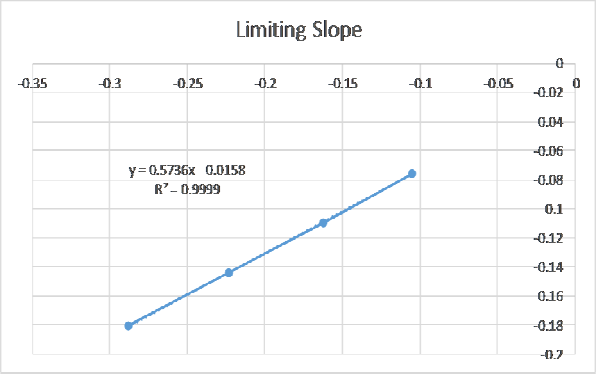

Fig 2B. Data for modified fractal analysis above is for a 58 year old type 2 diabetic man with history of Graves' disease and cigarette smoking who also has mild cognitive impairment. To determine Mn the vertical span of the liver, L, and the spleen, S, were measured as the 50% cutoff of peak activity in either organ using a 16 color scale as shown below and the liver anterior to posterior width was measured from a right lateral projection using a calibrated esoft tool. Body surface area used the Mosteller formula and BMi was in meters height and kg weight. Then Mn = (L)(W)(S)(1.6)(BMi)/(BSA)(23)(70).

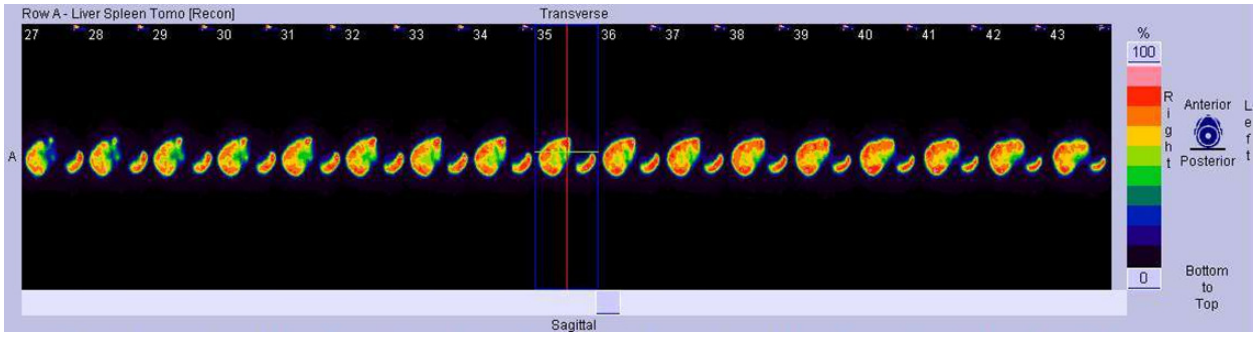

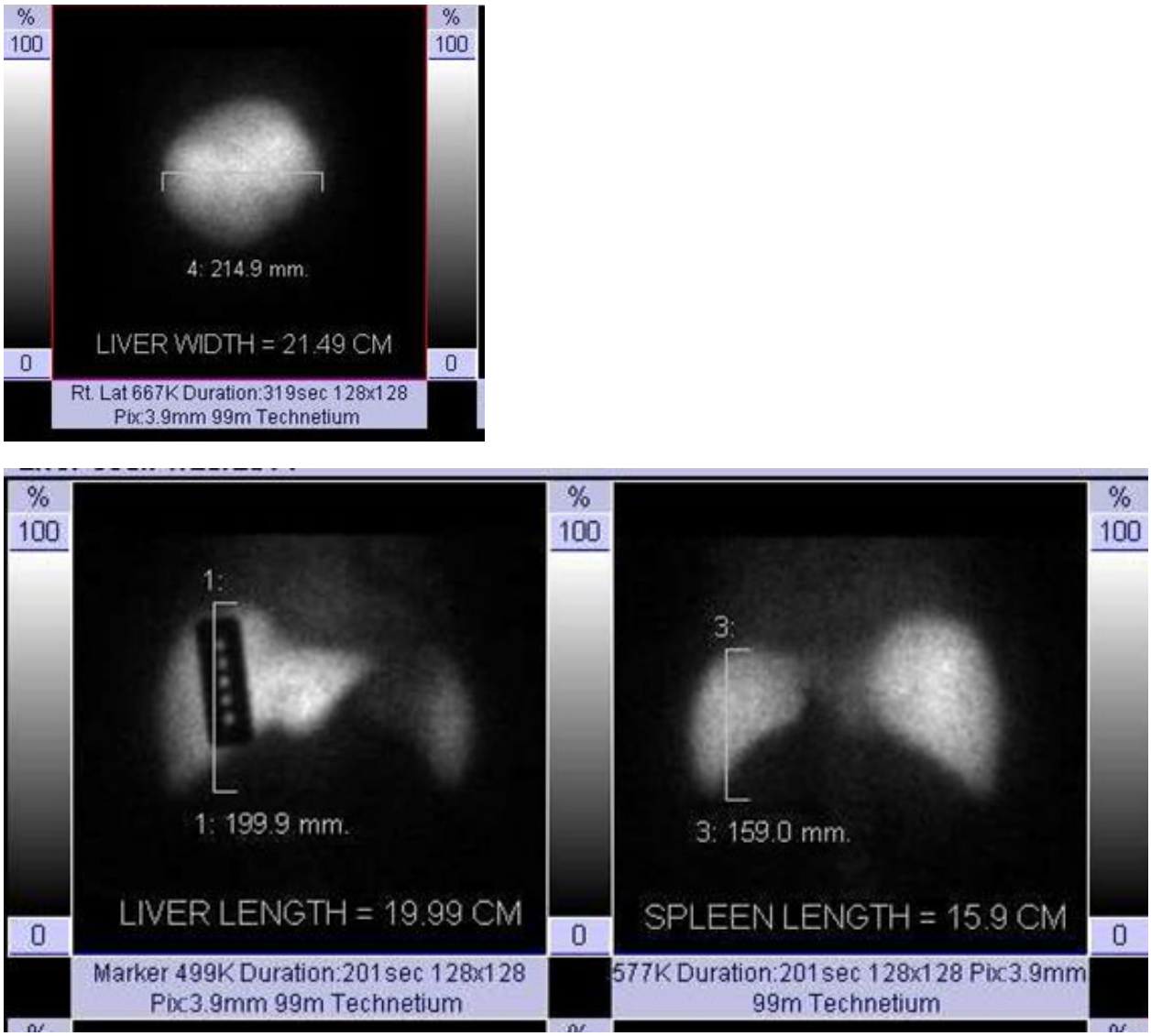

Fig 2C. Above is the planar scan of a patient with BMi 53.7. the highest value in this series, illustrating the effect of high BMi on liver dimension. Note that the anterior-posterior liver width is greater than the vertical span of the liver when BMi is high, as in this patient. Patients with low BMi, in contrast, typically have a much more vertical liver orientation with liver span significantly more than its anterior-posterior diameter.

3. Fig 3: Coronal SPECT images (ABOVE) on 8-15-2011 for 54 year-old type 2 diabetic (HbA1c 9.4%), alcoholic, cirrhotic man with advanced esophageal varices who was being treated with lactulose for hepatic encephalopathy and referred for hospice evaluation. Mn was 3.96. After abstaining from alcohol, successful varices ablation, improved glycemic control (HbA1c 8.6%) ,with insulin, and taking omega 3 fish oil 2 grams twice daily with food, as well as vitamin E 400 units daily, the patient improved remarkably. His Mn decreased on repeat SPECT of 12-16-2013 to 2.99 (BELOW) and even visually there is clear improvement in the degree of heterogeneity in his liver SPECT as well as improvement in portal hypertension, illustrated by the decreasing ratio of spleen to liver activity. Mortality within 2 years was 1/59 (1.6%) for patients classified with Mn > 2.77 used as the lower cutoff for cirrhosis.

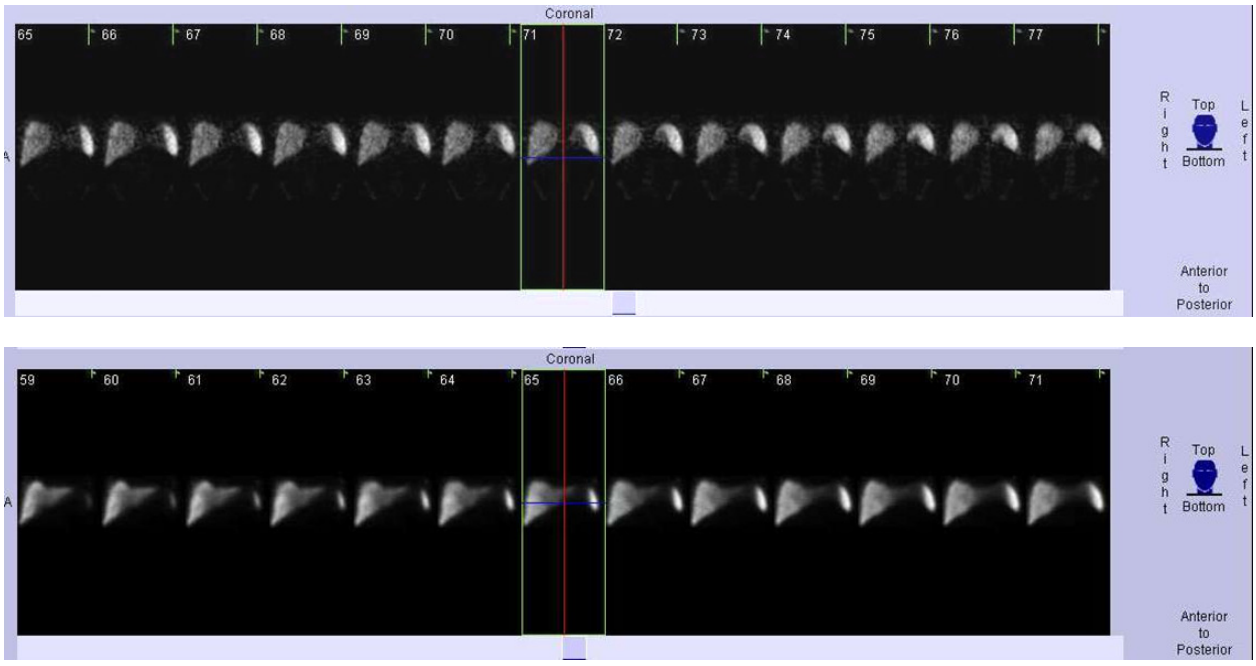

4. Fig 4A. Axial SPECT images on 7-29-2013 (ABOVE) for a 17 year-old insulin-resistant woman with initial BMi 42.5 and Mn 2.20 who was advised to follow a diet but refused other medical therapy. Her follow-up 1-2-2014 Axial SPECT images (BELOW) show increased portal hypertension and increased Mn 4.11 despite minimal weight loss, with BMi 42.0. Her prognosis for avoiding type 2 diabetes and its eventual complications is guarded.

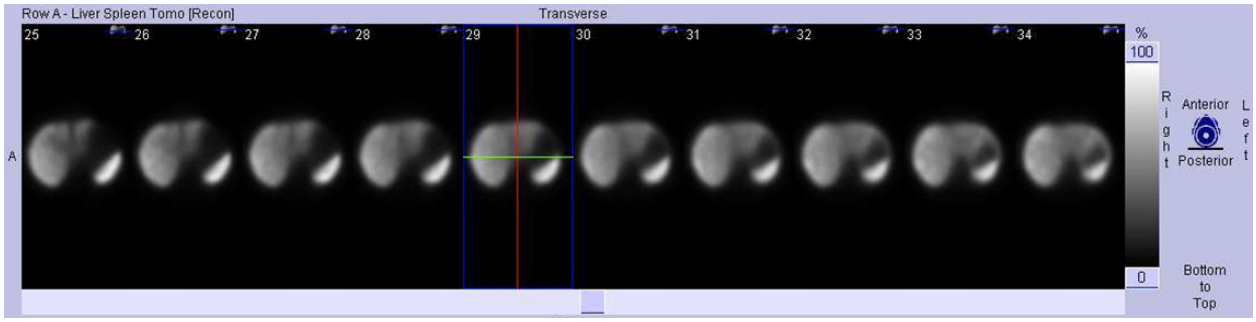

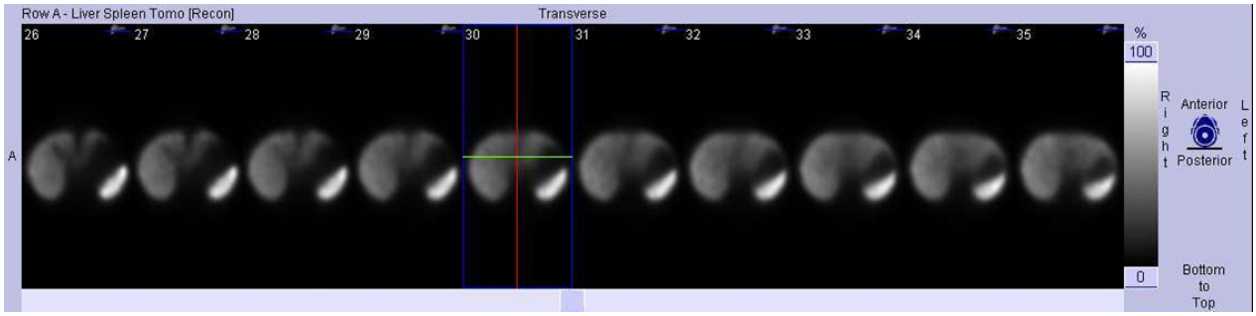

5. Fig 5: The modified fractal slope method was applied to an FDG PET (MIE America) scan for a 66 year-old type 2 diabetic man with biopsy proven rectal cancer.with SUV max 11.9. The whole body images (ABOVE) show three suspicious areas of hepatic activity. In delayed images only one of these continues to increase in activity (from SUV max 3.75 to 4.34) while the other two do not (ABOVE, RIGHT). When a modified fractal analysis is performed the tumor shows a clearly different slope than the normal liver tissue. Differences in slopes are not due to attenuation errors in the attenuation-corrected PET image, whose attenuation accuracy has been calibrated and found to be even more accurate than most other PET instruments (personal communication (Joe Ringelstein, Gamma Quality). This lesion of 1.2 cm diameter was confirmed malignant by follow up CT which showed that it increasing to 1.9 cm within several weeks.

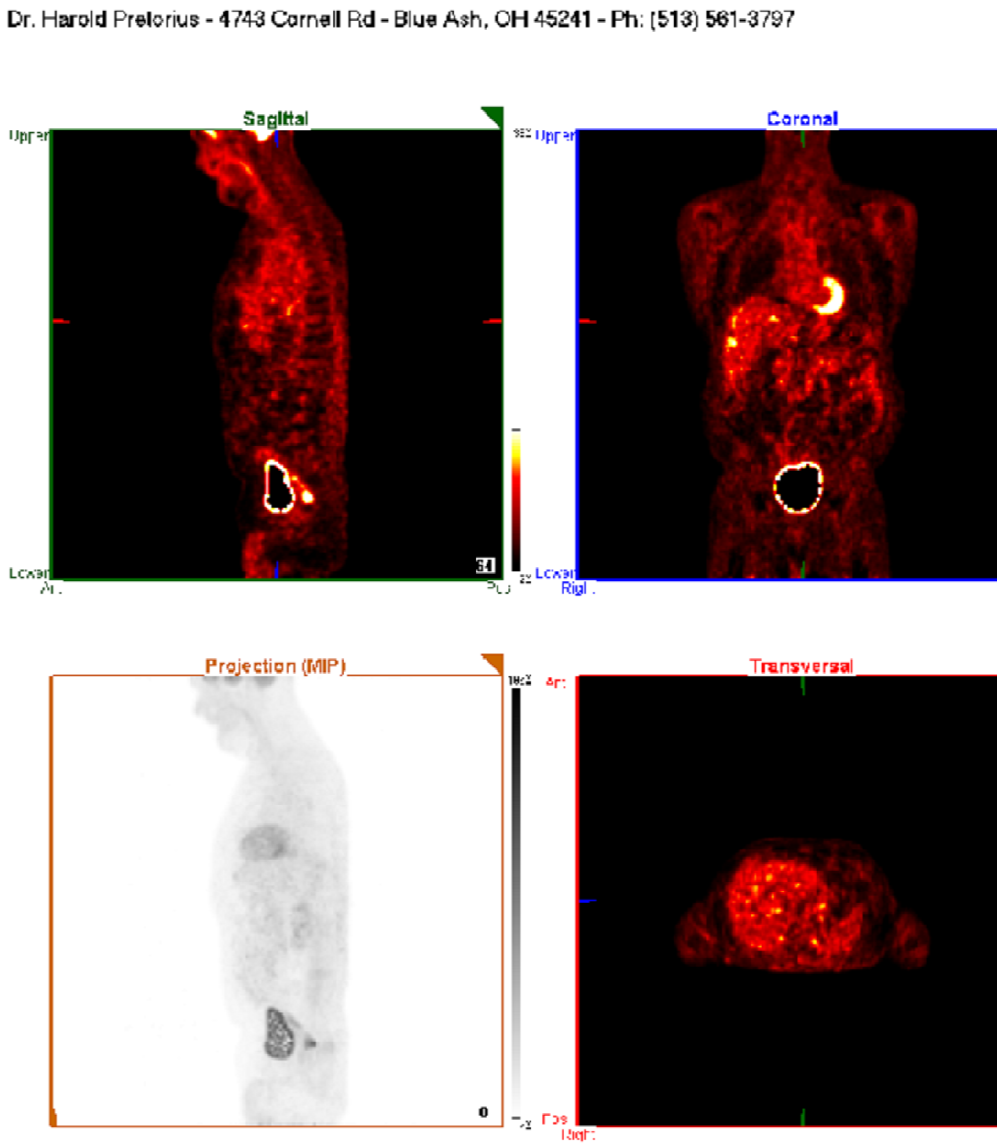

Dr. Harold Pretorius - 4743 Cornell Rd - Blue Ash, OH 45241 - Ph: (513) 561-3797



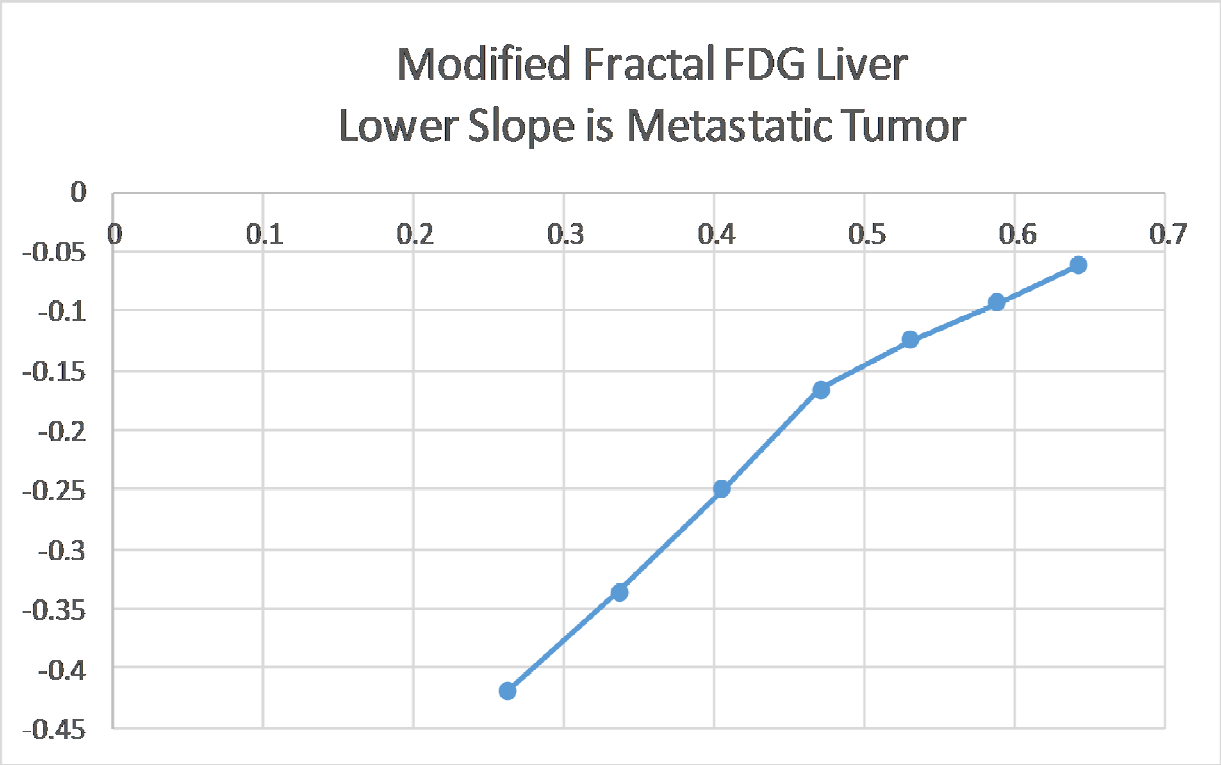
Modified Fractal FDG Liver
Lower Slope is Metastatic Tumor
0
-0.05
-0.1
-0.15
-0.2
-0.25
-0.3
-0.35
-0.4
-0.45
0
0.1
0.2
0.3
0.4
0.5
0.6
0.7