Abstract #809

Risk of Stroke in Pituitary Disease: Assessment by a Brain SPECT Index of Cerebral Flow Reserve

Harold T. Pretorius, MD, PhD, Luis F. Pagani, MD, Nichole M. Richards, CNMT, Dennis E. Menke, AA, John Idoine PysD, Shelley Haste, PsyD, Jerome J. Kelly, MD.

Objective: Use a brain SPECT cerebral flow reserve index (FRi) to assess stroke risk in pituitary patients with or without hypothalamic deficits (HD) vs. others with increased or near normal stroke risk.

Methods: Outpatients (n = 580) age (56+-14) years, 60% women, 40% men, 23% minorities, with neurologic complaints had basal and perfusion-stimulated brain SPECT using Tc-99m-ECD or Tc-99m-HMPAO IV.
Cortical metabolic (CMi), perfusion (CPi), flow reserve (FRi) indices and multicompartmental analysis (MCA) of brain, renal, and hepatic tracer concentration were computed for patients with pituitary disease (PD), diabetes mellitus (DM), hypertension (BP), renal failure (RF), liver failure (LF), traumatic brain injury (BI), clinical depression (CD), and near normals (NN). Neurocognitive testing included MMSE, TYM (Test Your Memory), Millon, SASSI, Beck, and selected psychiatric evaluation.

Results: NN patients (n = 25), age (54+-15) yrs, had CMi (60+-10)%, CPi (63+-10)%, FRi (5+-2)% and HD in < 2% vs. 70% (43/61) of PD, only 9.8% (6/61) of whom had macroadenomas. FRi = CPi – CMi was < 3% in 78% (46/59) of PD, similar to DM 61% (51/84) or BP 79% (64/81), but not uncomplicated RF 36% (18/50) or LF 25% (1/4). Initial MCA predicted that 50% decrease in renal or hepatic activity would cause > 15% increase in brain tracer activity, 1 to 5% increase in CMi and CPi, and 3% increase in FRi. Over 5 years, stroke or TIA occurred in 31% (19/61) of PD, 23% (16/70) of RF and 18% (15/84) of DM. FRi, HD, and neurocognitive measures trended to improve with > 6 months of incretin or other effective therapy for DM or PD. Correlation of abnormal orbitofrontal SPECT and CD occurred in > 50% of strokes and was also noted in 39% (29/61) of PD.

Discussion: Pituitary macroadenoma increases major stroke risk (pituitary apoplexy); however, stroke risk with more prevalent but more subtle PD such as microadenoma, trauma or opiate-induced PD (> 90% of this series) is uncertain. Frequent hypothalamic deficits on brain SPECT suggest a neuroendocrine basis of pituitary effects on brain perfusion. Conditions such as RF or LF, that decrease tracer blood clearance may result in increased brain concentration predicted by MCA, but do not necessarily decrease stroke risk.

Conclusion: Brain SPECT derived FRi is typically decreased in untreated PD and indicates an increased risk of stroke similar to patients with DM or RF. Hypothalamic SPECT deficits are also a nonspecific marker of PD and risk of stroke.

Abstract #809

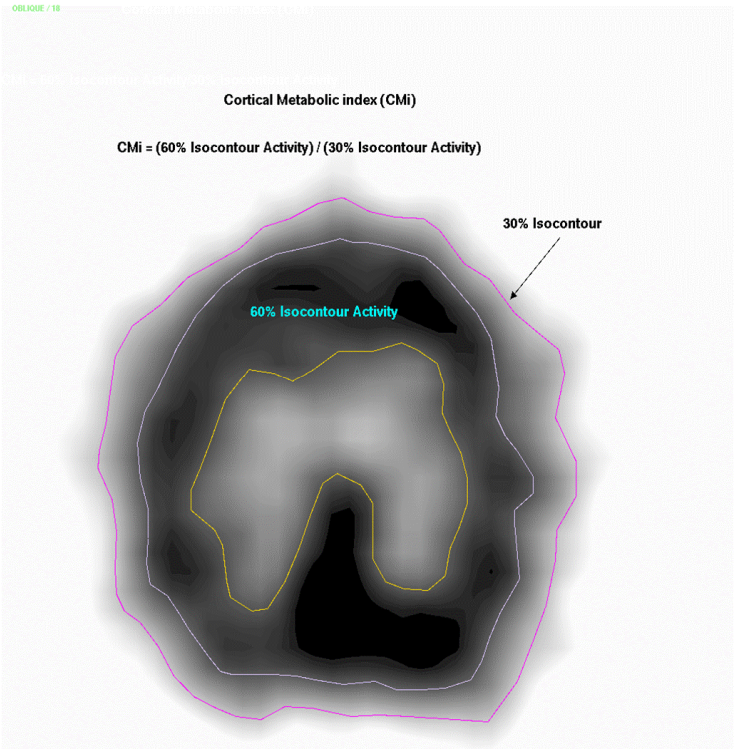

Fig. 1 (Above): Axial SPECT slices are defined parallel to the brain long axis from occipital to prefrontal. For the Cortical Metabolic index (CMi), one or more axial slices are centered one third of the way from the top of the brain, just superior to the roof of the normal-sized lateral ventricles. Activity display uses a Sokoloff color scale, with white for peak brain, black for zero and spectral colors for intermediate activities. Computer-selected isocontours define areas that contain activity above a certain fraction of the peak activity. The 30% isocontour represents total brain activity in that axial slice, chosen slightly outside the actual external edge of the brain (usually near a 60% isocontour) to correct for attenuation. The 60% isocontour represents the edge of normally functioning neurons, and the Cortical Metabolic index (CMi), calculated as the ratio of activity within the 60% to that within the 30% isocontours, is a measure of the fraction of brain function due to normal neuronal function. The Cortical Perfusion index (CPi) is similarly calculated from 60% and 30% isocontours after the patient has receives a cerebral perfusion stimulant such as 0.5 to 1 g acetazolamide IV or 0.4 to 0.8 mg nitroglycerin sublingual.

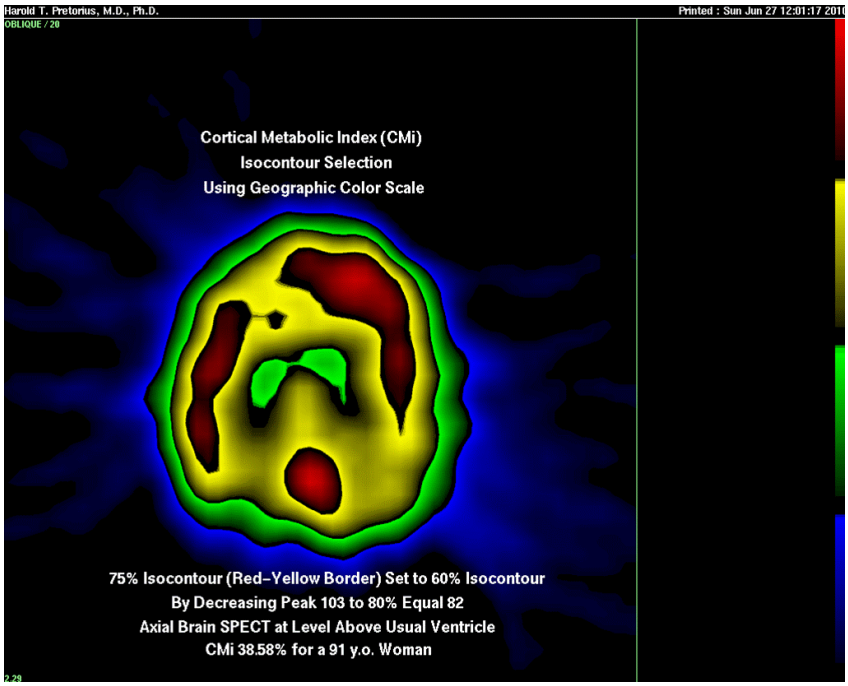

Fig. 2 (Above): The Cortical Meetabolic index (CMi) 38.58%, for a 91 year-old moderately demented woman is demonstrated using a color scale, available on nearly all commercial SPECT instruments. In patients with low likelihood of disease the values for Cortical Metabolic index (performed with patients injected with metabolic or basal blood flow tracers such as Tc-99m-HMPAO, Tc-99m-ECD or F-18-FDG) are 50 to 72% and for CPi increase to 53 to 75%. The Cerebral Flow Reserve index CRis simply CPi minus CMi, which is normally (defined in low likelihood disease patients) a positive number > 3%. We found previously that abnormal CR values < 3% or even negative numbers, are typical of cerebrovascular or associated disease such as diabetics, prediabetics, oxidative metal exposed and traumatic brain injured.

Abstract #809

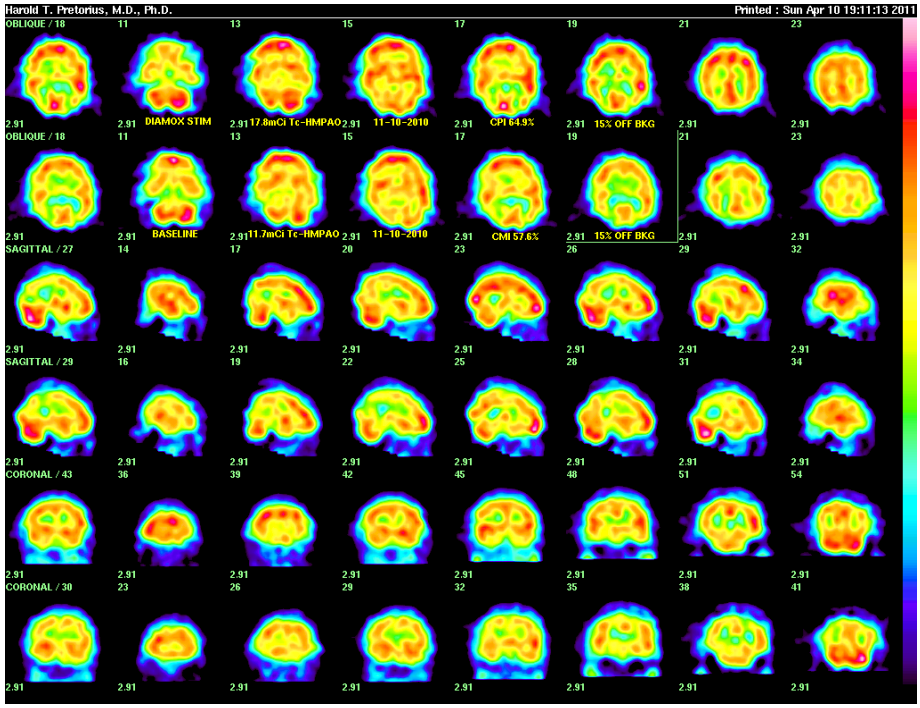

1. Fig 1: Above is a brain SPECT image, acetazolamide (Diamox) 500 mg IV stimulated, shown in the top of three paired rows of images, over basal images, shown on the bottom of three paired rows of images. The patient is a 56 year-old African American woman post subtotal thyroidectomy for multinodular goiter, euthyroid on replacement l-thyroxine and without significant menopausal symptoms on estradiol estrogen replacement. Her CMi 57.65 and CPi 64.9% are within normal limits (57-6+-7.1)% for CMi and (64.3+7.0)% for CPi among a total of 25 total patients with low likelihood of disease (near normals). Other clinical complaints among these patients included migraine headache, disability cases without apparent merit, patients with minor depression considered to have pseudodementia, and a physician with concern about possible minor memory impairment. No neurologic events were observed in these patients with an average follow-up of at least two years and several of them had repeat scans demonstrating stable or improving cortical indices, repeat evaluations without intervening therapy or clinical events (e.g. stroke) typically being within a standard error of approximately 3% in individual patients. The standard error of

recalculation of these indices by trained technologists is < 0.5%.

2. Table 1. A demographic summary of the patients

Descriptive Information	Overall (n = 580)
Sex / Age	
Female / Male (ratio) = 1.50	348 / 232
Mean Age (53.6+-15.9) Years ± Std; 19-97 (range)	
Race	
All Patients: 78.4% White 21.6% Others* Pituitary Patients: 79.8% White; 20.2% Others*	
In 25 Low Likelyhood of Disease Patients: **Cerebral Flow Reserve index (FRi)** = CPi - CMi	(6.67+-2.83)%
78.3% Low FRi (-2.9+-5.3)% in **Pituitary Patients** 87.0% Abn Low FRi (-4.0+-4.7) corr for Renal (FRi-3)% or Hepatic (FRi-6)% Insufficiency; p < 0.0001	54/69 60/69
31.9% had prior stroke or TIA	22/69
53.6% Hypertensive 36.2% Diabetes mellitus 11.6% Renal insufficiency: (GFR < 60 ml/min; Cystatin C > 0.85 mg/L)	29/69 25/69 8/69
.5.8% Atrial Fibrillation or SVT	4/69
69.8% **High BP; no Renal or Pituitary Disease**	141/202
49.6% Low Fri in Uncomplicated Hypertension	70/141
12.0% Stroke or TIA, Uncomplicated Hypertension	17/141
73.2% **Renal Pat**. Hyperten. without Pituitary Dis	60/82
31.7% **Renal Pat**. Abn Flow Reserve (0.67+-7.1)%	26/82
28.0% Renal Patients Stroke of TIA	28/82

* African American, Asian, Hispanic, or Mixed Ancestry.

53.2% Low FRi in **Diabetics** (82/154)
53.9% Hypertensive (83/154) when scanned
21.0% Stroke or TIA (33/154)
27.3% with renal disease (42/154)
13.0% with pituitary disease (20/154)

58.7% Low FRi in **Traumatic Brain Injury** Patients (37/63)
48.8% Pituitary disease in Traumatic Brain Injury (44/90)
16.6% Diabetics (15/90)
8.8% Renal disease (8/90)

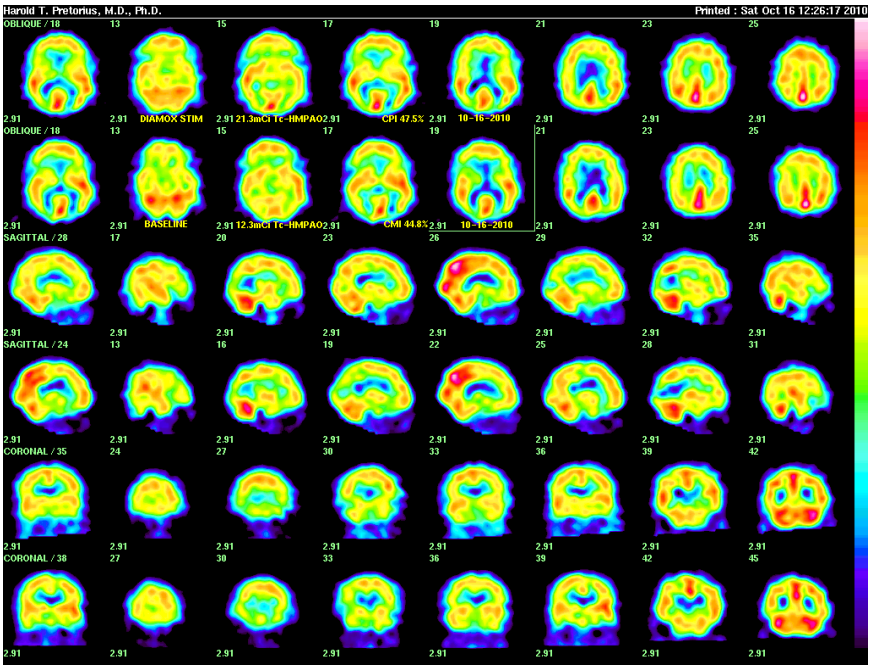

Fig: 3a: (above) A 46 year-old chronic pain patient with multiple osteoporotic thoracic spine fractures requires morphine sulfate 400 mg total daily oral dose and is pan hypopituitary, requiring testosterone, thyroid and adrenal replacement. His TYM test is 46 of 50, which is within normal limits (scores < 42 are consistent with cognitive impairment). MRI of the pituitary including dynamic images with contrast. His SPECT scan on the right shows acetazolamide stimulated perfusion (top of each of 3 paired rows of images) over basal images (bottom of eac of 3 paired rows). The Cerebral Flow Reserve index CFi, is given by CPi 47.5% minus CMi 44.8% = 2.6%, at least one standard deviation below the mean CFi = 6.56+-2.83. Findings include prominent ventricles consistent with functional cerebral atrophy more prominent than expected at age 46 years, orbitofrontal hypoperfusion, evident in each of the first saggital images (17 perfusion-stimulated and 3 basal), patchy basal ganglia activity (saggital images 26 and 22), right mesial temporal (coronal 33) and inferior temporal (coronal 39) hypoperfusion, bilateral posterior parietal hypoperfusion (axial images 19) and wedge-shaped occipital hypo-perfusion mainly in the stimulated images (saggital 29). Perfusion-stimulated cerebral ischemia is likely from this finding and consistent with risk of stroke which may affect the visual cortex. Subjectively, the

patient did have evidence of right homonymous hemianopia. Pituitary disease as a consequence of chronic opiate therapy is increasingly recognized and was a possible factor in 34% of 69 patients in this series.

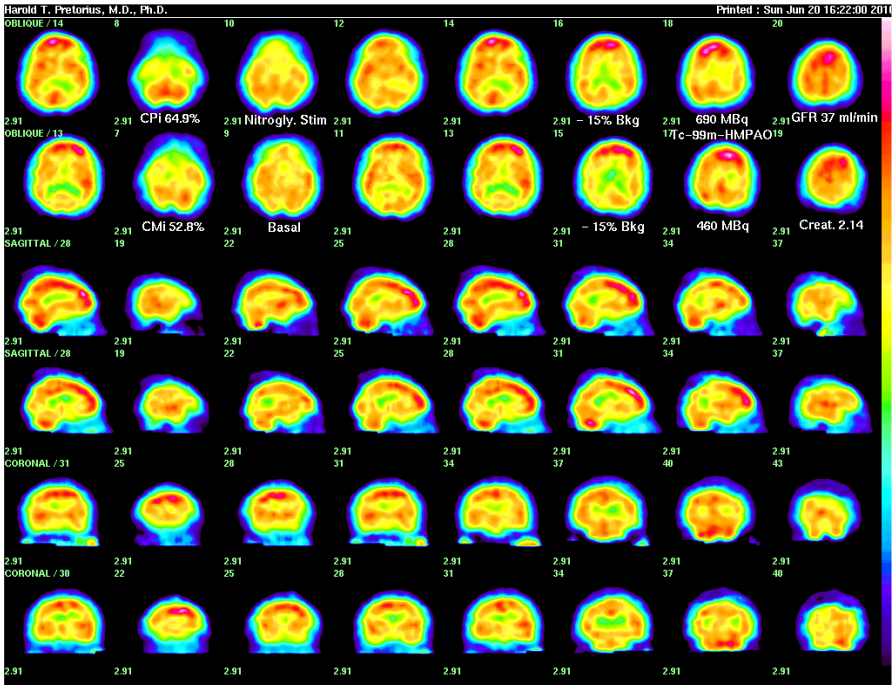

Fig 3b: (above) Brain SPECT on the right with 0.8 mg nitroglycerin sublingual used for perfusion-stimulated images (top row of each of 3 paired rows of images; basal images are on the bottom row of each of the 3 paired rows) in a 75 year-old hypertensive African American man with relatively stable renal insufficiency. Serum creatinine over the last 2 years was 1.60 to 2.25 mg/dL, and near the time of imaging, 2.14 mg/dl, corresponding to GFR 35 to 45 ml/min. The patient has Mild Cognitive Impairment but normal cerebral flow reserve (FRi), here (64.9 minus 52.8)% >> 3%. Among 81 hypertensive patients average age (57.3+-14.5) years, without renal dysfunction, only 31.7% (26/82) had ab normally low FRi.

Abstract #809

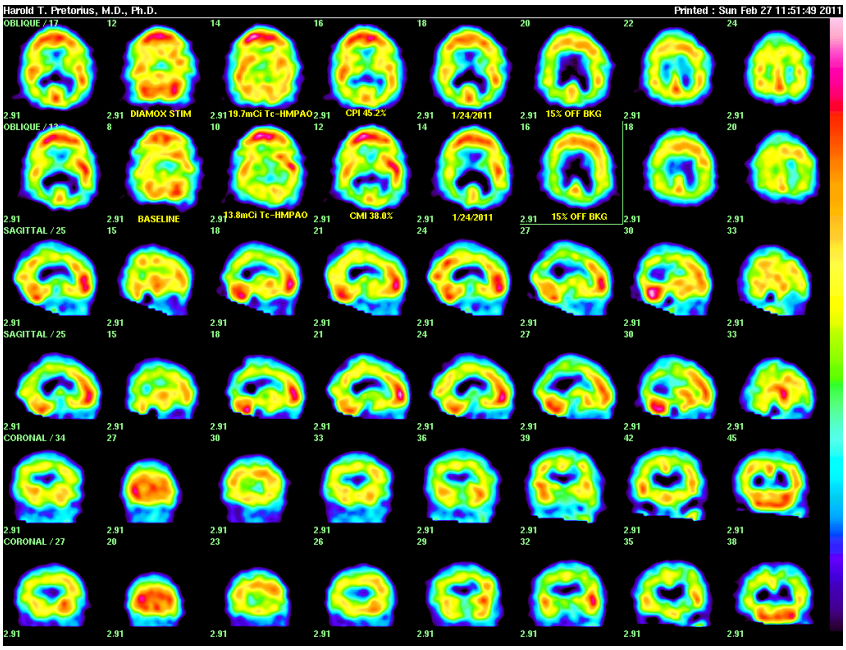

Fig. 4a: (above) A 28 year-old woman post craniectomy (third ventriculostomy) for hydrocephalus associated with a hemangioma of the third ventricle has mild diabetes insipidus with serum sodium 152, chloride 111, BUN 14, creatinine 0.84 mg/dl after hydrocortisone replacement with hydrocortisone for decreased adrenal reserve, when serum cortisol was 34 mcg/dl. Other pituitary abnormalities included elevated IGF1 358 ng/ml (normal range 117-329) and borderline high alpha subunit 0.36 ng/ml (normal 0.04-0.38) despite normal LH 9.1 mIU/ml, FSH 6.1 mIU/ml, Free T4 1.45 (0.82-1.77), TSH 0.835 ().450-4.50) and revT3 306 (90-350) as well as normal prolactin 13.1 ng/ml (6.2-19.1). The patient complained of stuttering and intermittent inability to concentrate, migraine headaches, tachycardia and chest pain. Her friends noted episodes of suicidal depression, although she had a normal Beck depression index of 7 (nml <10, extreme depression > 40) while taking sertraline 50 mg oral daily and near normal psychiatric interview. Her urine porphyrins revealed elevated corproporphyrin I of 35 mcg/L (nml 0-15) and corproporphyrin III of 121 mcg/L (nml 0-49) suggesting possible neurotoxic metal exposure, similar to approximately 15% of all patients with cognitive complaints encountered in our clinic. Apart from the evidence of mild diabetes insipidus, which did not require DDAVP, the patient has repeatedly verified normal renal function, despite quantitative immunoglobulins revealing borderline Immunoglobulin A deficiency and history of recurrent mucocutaneous infections incluing otitis media with vertigo, pharyngitis and bronchitis.

Her brain SPECT shows acetazolamide stimulated perfusion (top of 3 rows of paired images) over basal perfusion and is noteworthy for ventriculomegaly (confirmed on MRI), hypoperfusion of the basal ganglia, mesial temporal lobes and parietal and occipital lobes bilaterally. The frontal lobes are remarkably intact.

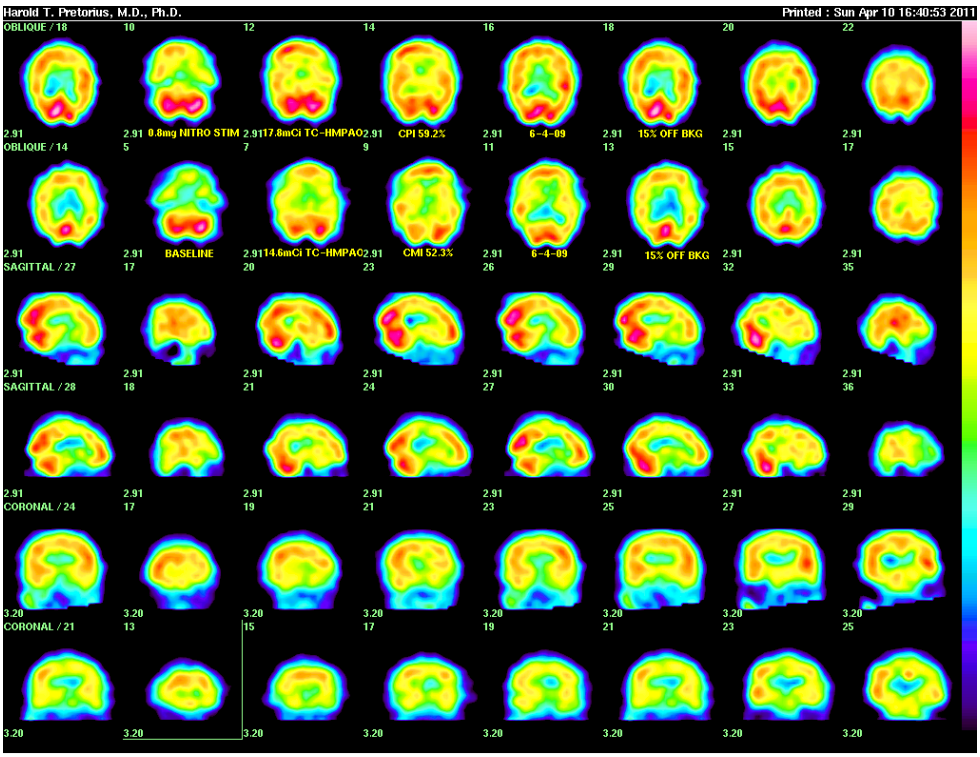

Fig. 4b: (above) A 75.6 year-old Caucasian woman with serum creatinine 1.80 mg/dl,GFR 29 ml/min complains of memory loss, dizziness and chronic back pain requiring chronic opiate therapy. Her MMSE is 25/30 and TYM 49/50. Without correction for renal insufficiency, her FRi (59.2 - 52.3)% = 6.9% is normal and with a flat correction of 3.0% used in this study (perhaps more applicable to earlier stages of renal insufficiency) it remains normal, at 3.9%. She does have hypothalamic hypoperfusion most easily appreciated in mid saggital and coronal images below.

Abstract #809

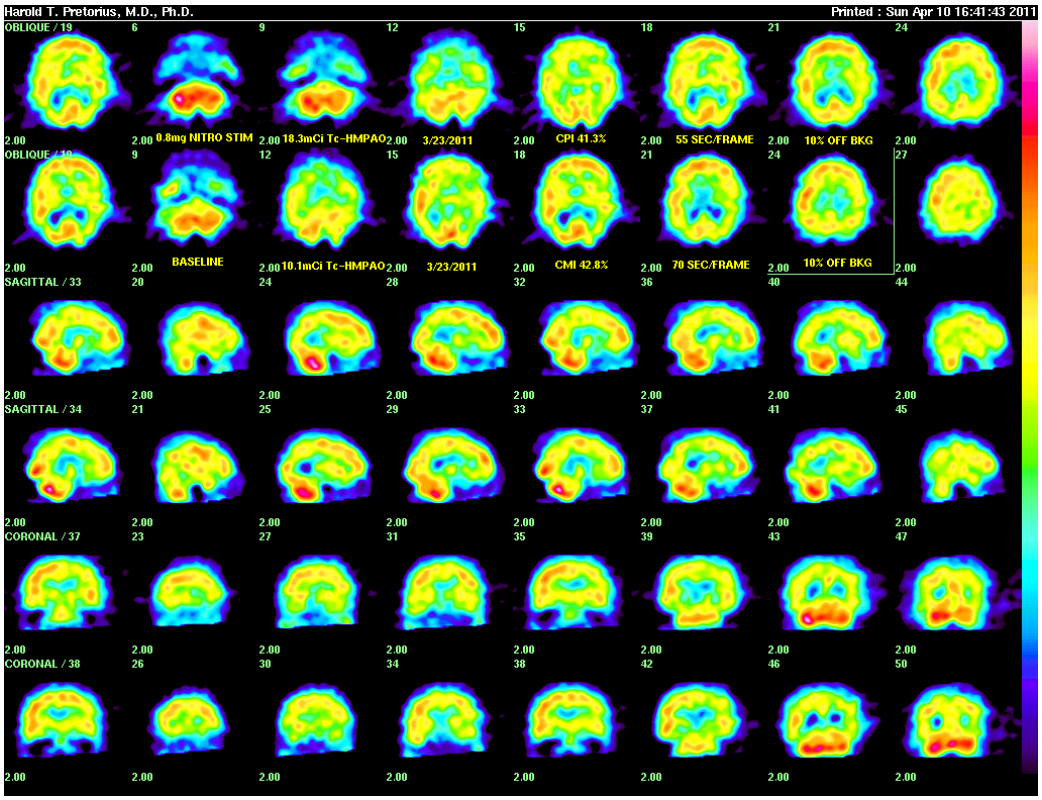

Fig 4c: (above) Follow-up brain SPECT for the now 77.4 year old woman of Fig 4b shows compromised CMi 47.8% and CPi 41.3% with FRi –6.5% (corrected –9.5%) after her serum creatinine increased to 2.80 mg/dl, GFR 18 ml/min and her TYM decreased to 45, consistent with progressive memory loss. A new left parietal deficit (saggital 32) and patchy temporal deficts (coronals 27-34) suggest progressive cerebrovascular disease and orbitofrontal deficits (lateral saggital images) suggest associated psychiatric depression.

5.

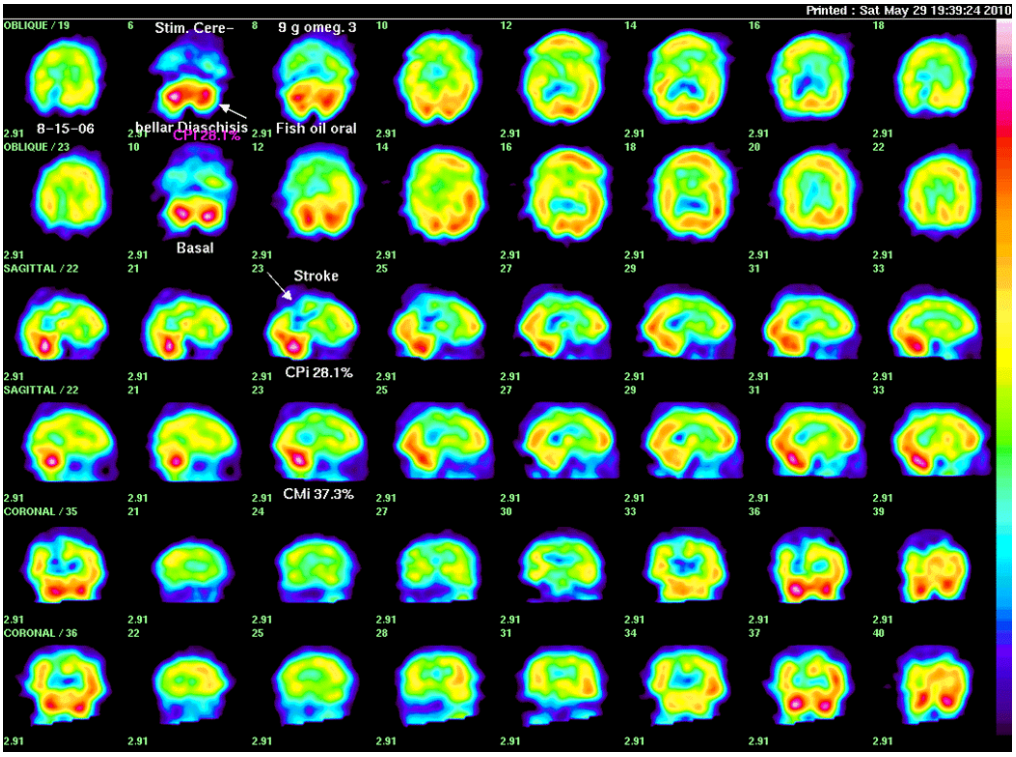

Fig. 5a: Above is SPECT for an 86 year-old woman with renal failure, serum creatinine 2.6 mg/dl, cystatin C 2.75 mg/L, and GFR 22 ml/min, exemplifies exception to the usual preservation of FRi with renal failure which is usually observed prior to stroke. The top row of each set of 3 paired images is post perfusion stimulation, using 10 g of fish oil in this case, which we have repeatedly shown is similar to either acetazolamide IV or nitroglycerin sublingual. A right posterior parietal stroke is easily appreciated. Saggital image 23 shows further decreased perfusion in the penumbra area as compared to the basal images below.

Abstract #809

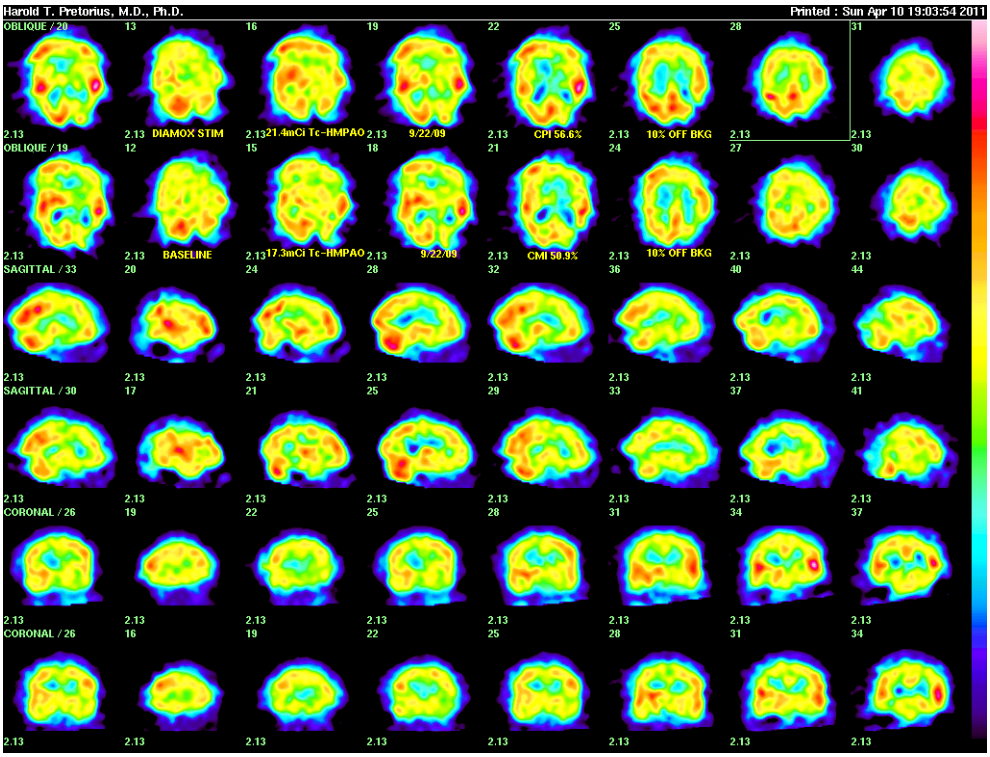

Fig 5b: (above) Positive Effect of Incretin Therapy: A 56 year-old hypertensive, type 2 diabetic woman with memory loss (MMSE 26/30 and TYM 29/50) had abnormal CMi 50.1% and CPi 44.2% (abnormal CFi –5.9%) on baseline brain SPECT. Follow-up Brain SPECT after two years, shown below reveals CMi 50.9% and CPi 56.6% with normal CFi 5.7%, cf. low likleyhood of disease patients CFi (6.67+-2.83)% after control of hyopertension with aliskirin (Tekturna), hyperlipidemia with atorvistatin (Lipitor) and glycemic control (for two years) with exenatide (Byetta). Stoke prophylaxsis in this patient was cilostazol 100 mg oral twice daily. Her memory also subjectively improved and TYM increased from 29/50 to 34/50.

6.

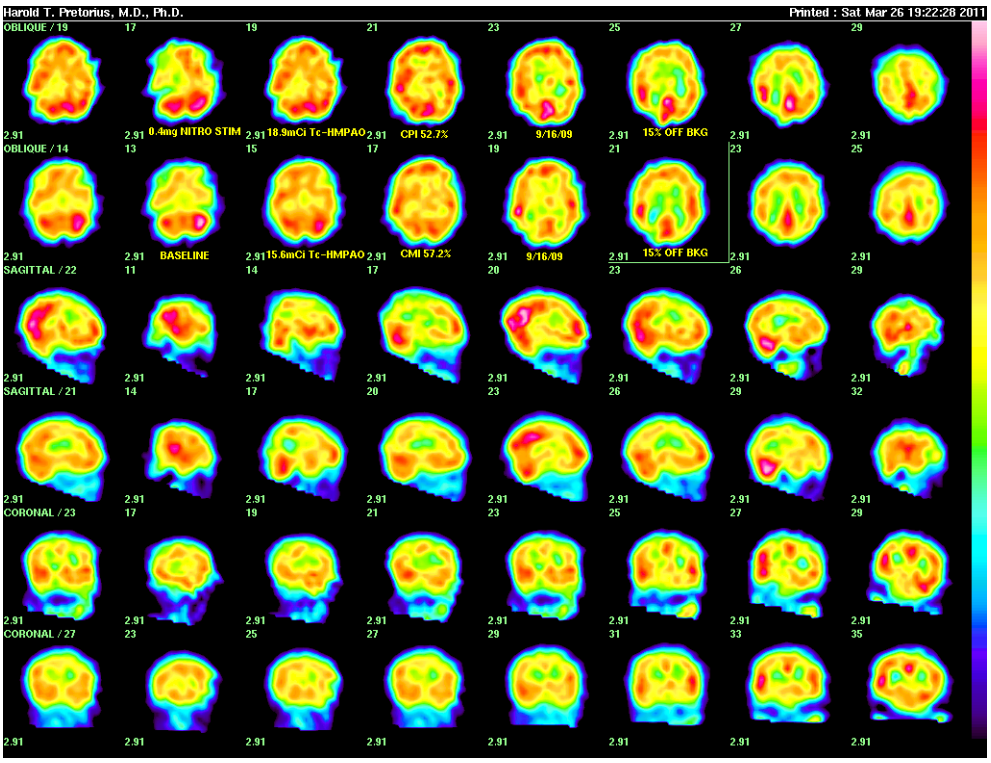

Fig. 6a: (above) A 44 year-old insulin-resistant (IRS) woman with hypertriglyceridemia and difficulty controlling her weight suffers from migraine and syncopal spells after a motor vehicle accident. She has borderline stage 3 renal insufficiency with glomerular filtration rate 56 ml.min at the time of brain SPECT shown on the right which shows minor abnormalities including a wedge-shaped right frontal defect (axial 29), posterior right parietal minor deficit (Axial 25) and decreased cerebral flow reserve index, CFi = 52.7% - 57.2% = - 4.5% (normal > 1.0%). Correction of CFi for renal insufficiency would make CFi even more abnormal, approx. –7.5%. Abnormal CFi is seen in about 65% of patients with IRS, similar to diabetics (reported previously in The International Vascular Dementia Conference, Barcelona, Spain, 2009).

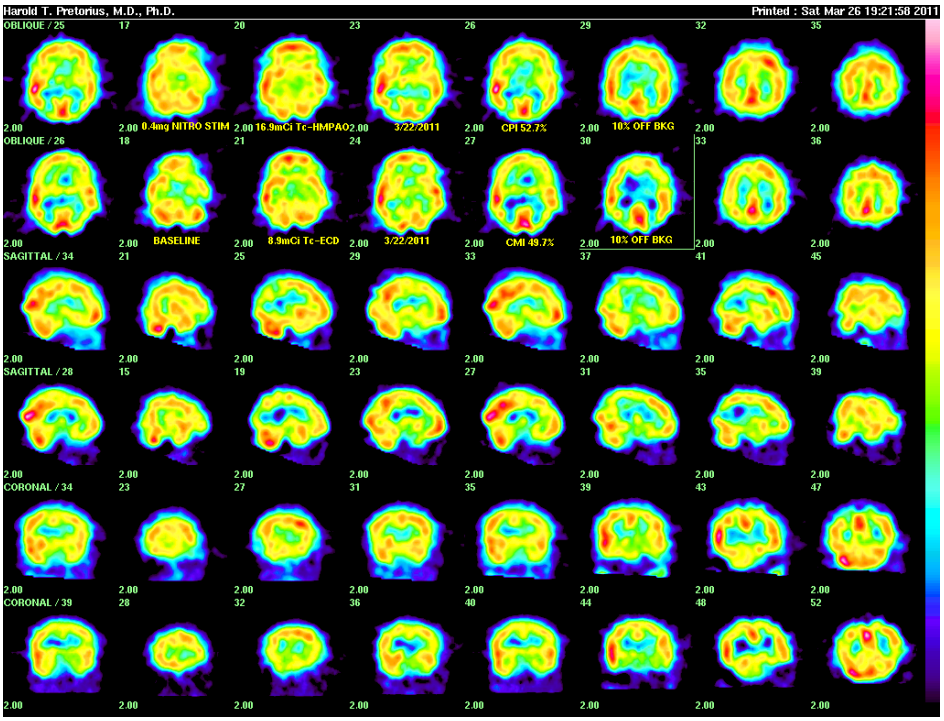

Fig. 6b: (above) The same, now 46 year-old woman whose brain SPECT was shown above (Fig 6a) is involved in a more serious motor vehicle accident (combined impact speed > 50 miles/hr) and although she does not recall losing consciousness, suffers acceleration-deceleration traumatic brain injury (TBI) accompanied by a post concussion syndrome, with exacerbation of migraine headache, difficulty concentrating and lightheadedness. She also has even more difficulty with controlling her weight and gains several pounds within a week. Although TBI patients often show abnormality more prominently in perfusion-stimulated brain SPECT, this patient's basal study (bottom row of 3 paired image rows to the right) shows more prominent basal ganglia abnormality, patchy temporal deficits, bilateral posterior parietal and patchy periventricular hypoperfusion. Her renal function at the time of the follow-up study is normal. Use of Tc-99m-ECD, which more closely mirrors F-18 fludoexyglucose determined cerebral metabolism, for the follow-up basal study may also have enhanced recognition of subtle metabolic abnormalities. Initial evaluation of pituitary function in this patient was normal, although up to 30% of TBI patients will demonstrate eventual pituitary dysfunction.

7.

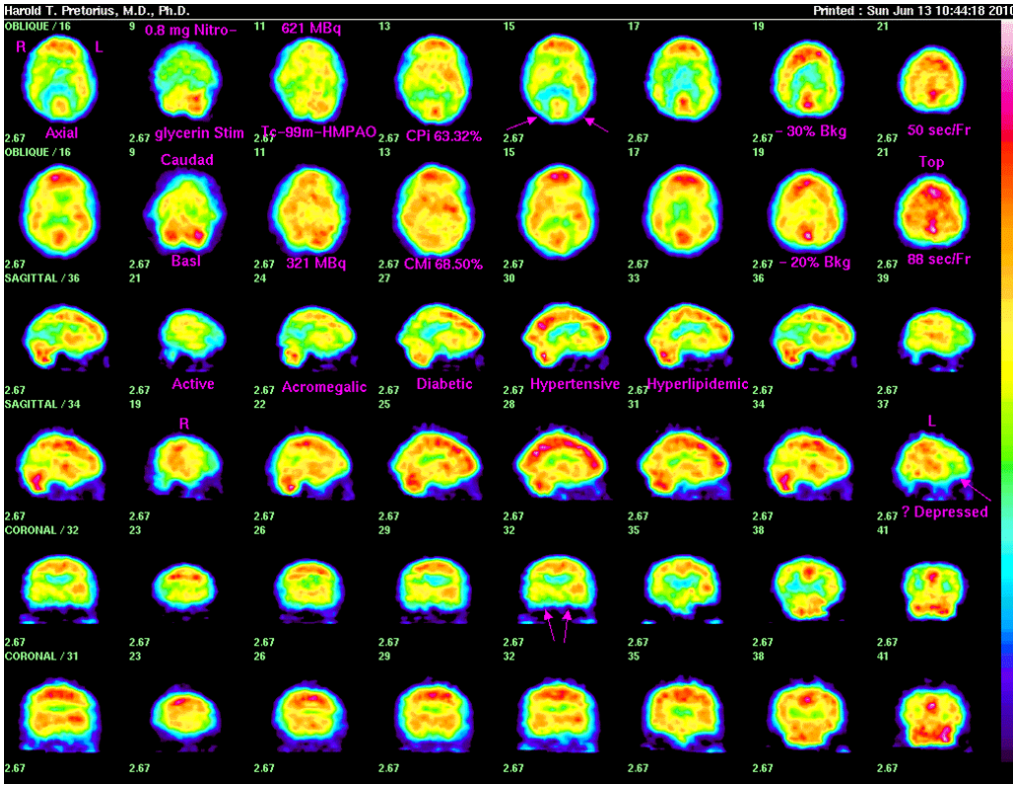

Fig. 7a: (above) Acromegalic 62 year-old man, post hypophysectomy, with persistant pituitary tumor activity documented by incompletely suppressed somatomedian C (Insulin-Like Growth Factor 1) 283 ng/ml (normal 76-212 ng/ml) by Somatulin therapy has mild cognitive impairment (short-term memory loss requiring frequent notes) and renal insufficiency: serum creatinine 1.61 mg/dl and GFR 44 ml/min. Multiple metabolic risk factors including active pituitary disease, hypertension, type 2 diabetes mellitus and hyperlipidemia appear to overcome the usual effect of renal insufficiency to preserve CR, which is abnormal here since CPi 63.32% minus CMi 68.50% << 3%. Peak contribution of the basal image to the nitroglycerin-stimulated SPECT is 20%; however, only 10% additional background is subtracted beyond a scattering background taken as 20% here, which emphasizes bilateral parieto-occipital and mesial temporal deficits typical of amnestic mild cognitive impairment.

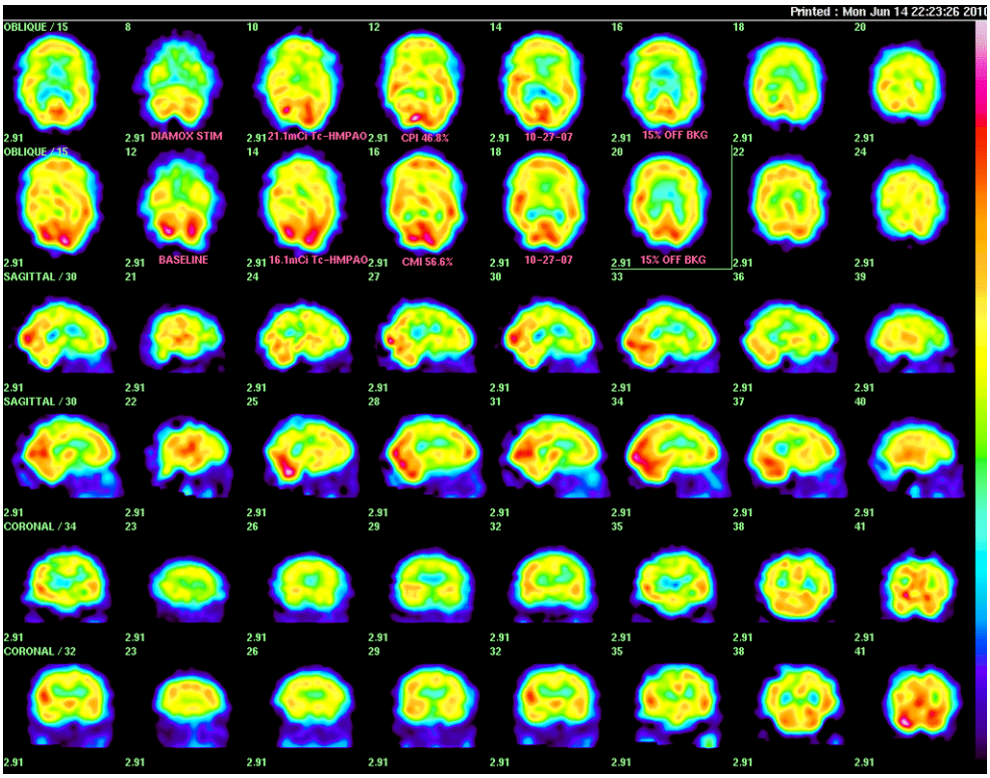

Fig.7b: Above are SPECT images for a 71 year-old hypogonadal, type 2 diabetic man with hypothalamic hypoperfusion and stable renal insufficiency, GFR (46.4+-3) ml/min over 2 years, whose CR (46.8-56.6)% < 3 is also abnormal. Of a total of 4 pituitary patients with renal insufficiency, 75% (3/4) were exceptions to the usual observation of normal CR, these 3 together with 10 scans in 8 stroke patients (one of whom had pituitary apoplexy) accounting for 13/19 = 68.4% of the total number of such atypical cases.

Both this patient and the pituitary patient shown in Fig. 7a (above, left) have small left orbitofrontal deficits (arrow above, saggital image 37) and above, in Fig. 7b in saggital images 36, 39 which may be associated with depression, these two correlated in 80.4% or 37/46 of pituitary patients (at least 53.6%, 37/69 of whom were clinically depressed). Depression may thus be yet another stroke risk factor associated with regional cerebral hypoperfusion, and interrelated to other risk factors: cf the known strong associations of depression with stroke and with diabetes mellitus. We observed that depression-associated cerebral hypoperfusion, even in patients with history of resistant depression, may either

resolve or be exacerbated acutely by incretin therapy, specifically, pramlintide (Symlin) 90 mcg sq or exenatide 10 mcg sq and that exenatide (Byetta) over 2 years improved cerebral flow reserve (Fig 5b).